

Purpose of cephalometric computations in craniofacial surgery

A. TOMAKA* and L. LUCHOWSKI

Institute of Theoretical and Applied Computer Science, Polish Academy of Sciences, 5 Bałtycka St., 44-100 Gliwice, Poland

Abstract. The main goal of this article is to present ways of creating a parametric, dynamic model of the physical frame of the human head in order to cope with the badly disfigured patient's appearance, affecting various functions (e.g. breathing, speaking, chewing and swallowing).

Key words: cephalometric computations, craniofacial surgery.

1. Introduction – purpose of cephalometric computations

Orthodontics is a branch of medicine concerned with the shaping of the craniofacial area of the skull, i.e. the teeth, jaws, palate, and adjacent bone structures. Developmental, posttraumatic, or postoperative deformations in this area affect functions such as breathing, speech, chewing and swallowing. The patient's appearance is often badly disfigured, which also has a severe impact on the quality of life.

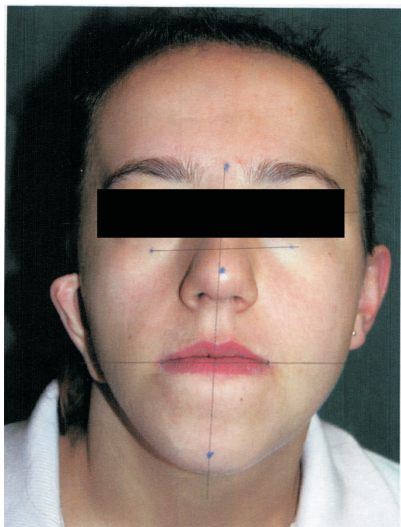

Fig. 1. Face of an orthodontic patient, lines indicating asymmetry

For over a century now, orthodontists have used sophisticated geometric constructs to study various incorrect conditions, to plan treatment, and to evaluate results.

Image-based data acquisition in orthodontics is carried out in three steps:

- acquiring a calibrated image of the patient's craniofacial area by radiological techniques (traditional Xray, CT, MRI...),
- identifying structures of interest in the image,

- computing derivative parameters describing the patient's condition.

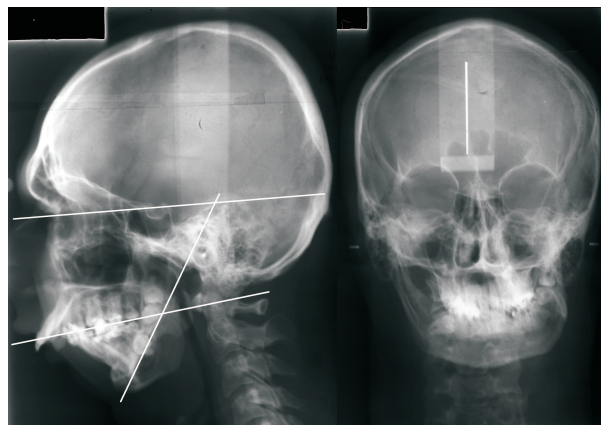


Fig. 2. Lines drawn manually over a cephalogram to emulate traditional measurements

The data is collected and further processed for a number of purposes, including

- statistical analysis and creation of diagnostic standards,
- evaluating a patient's condition against these standards,
- monitoring changes due to natural growth, disease, and treatment,
- planning corrective interventions such as osteodistraction and surgery,
- predicting future development and long-term effects (both functional and cosmetic) of intended treatment. This includes estimating the future shape of the bone frame as well as the outward appearance of the face.

2. Our goals

Much of our work is dedicated to bringing together the data from various imaging modalities such as CT, MRI, and optical (i.e. visible-light) surface scanning of the head and in particular of the facial area [1, 2]. Every 3D image is taken in a certain coordinate system, often associated with the

*e-mail: ines@iitis.gliwice.pl

imaging device, and unrelated to other devices. Even if the same device is used again on the same patient at a later date, the mutual positioning of the patient and the device cannot usually be reproduced.

We have created various reference frames, based either on anatomical landmarks or artificial physical reference objects, which allow images to be brought into register.

Our ultimate purpose is to create a parametric, dynamic model of the physical frame of the human head.

The model should be capable of accommodating any information available, either by direct observation or inference, at a given point in time. Inference here refers to identifying and using at least three types of approximate relationships:

- **Bone at time T1** → **bone at time T2**: using imaging data from a previous point or points in time to estimate the present situation without repeating the imaging procedures.
- **Bone** → **skin (and other soft tissues)**: using the present data – both observed and inferred – to forecast how the appearance of the patient will change as a result of future development and long-term effects of planned treatment.
- **Skin (and other soft tissues)** → **bone**: using the external shape of the head (accessible by optical scanning or other non-invasive techniques) to estimate the underlying bone structure.

All information, both obtained from measurements and inferred via the model, should be merged and presented so as to clearly indicate what is known about the patient's condition and what aspects remain unknown or uncertain.

The expected medical benefits from such a model are manifold:

- reducing X-ray exposure, which is especially important in the case of children and adolescents;
- assisting the orthodontists, surgeons, and patients in making more informed decisions;
- documenting case histories for the purposes of further medical research such as defining standards and developing treatment techniques.

3. Techniques used and results achieved

Our initial work consisted in creating a computerized version of the traditional techniques of cephalogram analysis. Two perpendicular X-ray projections (Anterior-Posterior and Lateral-Lateral) of the patient's head were displayed on the screen, and a medical expert using a mouse was asked to indicate a number of anatomical feature points. The computer then performed operations which had traditionally been carried out using pencils, rulers and compasses, computing distances, angles and generating various derivative parameters. While technologically outdated, these purely 2D measurements had the advantage of being accepted and meaningfully interpreted by medical specialists, thanks to the existence of established standards.

One of the obvious drawbacks of 2D X-ray images is the loss of one dimension. The images of different anatomical

structures appear superimposed and can be difficult to distinguish. Another problem is the difference in magnification of various parts of the head. Depending on how far they are from the film or sensor, one side of the head can be imaged with a magnification factor of 1.08, while the other is magnified by a factor of 1.2 [3].

A number of research projects used the principles of stereovision to derive 3D information from a pair of cephalograms. The Bolton Brush Growth Study Center built an imaging station [4] consisting of two X-ray devices oriented at 90° to each other. In our laboratory [5], we implemented a similar functionality in software, using two approximately perpendicular X-ray projections taken with one device, with the patient in two different positions. Unlike the Bolton Brush system, the relationship between our two projections was not predetermined and had to be identified for each pair of images. Metal stereotactic frames with pointed markers were built in order to provide clear reference points and relate the images to each other. The frames were attached to the subjects' head (or, in some of our experiments, to a dry skull) prior to taking the two X-ray images. The points were identified in each image and allowed the fundamental matrix to be estimated.

The spread of fully 3D medical imagery brought with it a new perspective on the geometry of the craniofacial region. The question arose who, and how, should create a new set of parameters describing the spatial relationships between feature points, planes and lines. We have met situations where the medical professionals looked to technical specialists for guidance on what they perceived as a mathematical issue, while the IT researchers expected the medical staff, as the intended final users, to specify their needs.

3.1. Image registration and calibration. Our first scanner, the Minolta VI9i, could only scan a narrow sector of the head at a time. Outside this sector, the angle between the laser beam and the surface normal was too large for reliable scanning. Scans from eight different directions, by moving the scanner manually around the patient, and then brought into one coordinate system [1, 2].

Registration was relatively simple for overlapping static visible-light scans of heads, where the eight images acquired from eight viewpoints surrounding the patient could be brought into register using a standard surface-matching procedure. Even so, much manual processing was needed to smooth out the joining lines, fill gaps, and remove redundant layers, in order to ensure a regular topology of the whole.

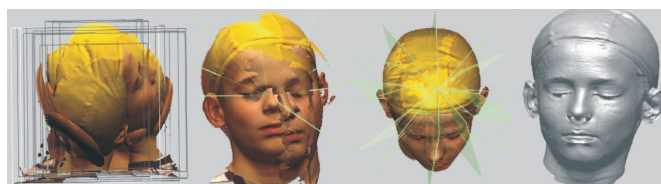


Fig. 3. Successive stages of registering and merging eight scans of a head (the leftmost picture shows them in their initial, unrelated coordinate systems)

Another registration problem arose when plaster models of the dental arches (made from casts taken from the patient) were scanned as separate objects. The scans provided very good 3D renderings of the shape of either dental arch, but their coordinate systems were independent of each other, and of that of the image of the face. We used a facial arch with additional markers in order to bring all three models into register [6]. The final result is a 3D representation of the external shape of the face with the shapes of the casts correctly positioned inside.




Fig. 4. Using a facial arch to bring casts and face into register

Significant effort has also been dedicated to identifying the gantry inclination in CT imagery [7]. The gantry is the large assembly carrying X-ray sources and detectors, and it can be tilted at various angles so as to more flexibly select the volume to be imaged. A drawback of this option is that the resulting images are represented in an oblique coordinate system, the angle of which must be known to correctly interpret the data. In principle, the angle is stored along with the image in the DICOM format. However, we have found that software from various manufacturers does not use the same convention to store the tilt angle, or in some cases ignores it at all, leading to badly distorted images. Calibration techniques had to be developed to reconstruct the angle from image data.

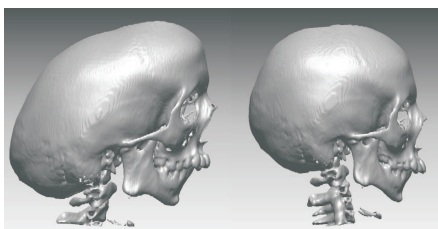


Fig. 5. Two 3D images of the same human skull; left image distorted due to gantry tilt error

Our work towards building a parametric and dynamic model of the head is still far from complete, but some solutions have been found in each of its aspects.

3.2. The bone(T1) → bone(T2) aspect. To describe the growth of a complex biological structure we need some simplifying assumptions. One possibility we exploited was representing the skull by a set of anatomical feature points manually localized by medical experts. Change was represented by affine transformations in a three-layered model:

- The global deformation tensor is the coefficient matrix of the affine transform that best approximates the overall change of the shape of the set of points;
- The local deformation tensor, determined for anatomically significant subsets of points such as the mandible, is a similar matrix determined for the corresponding anatomical area;
- The interpolated deformation tensor is a tensor field estimating the growth within an anatomical area. It is generated by assigning the local tensor values to central points of their support areas, then interpolating between them and ensuring smooth transitions between areas.

The deformation tensor, and the affine transform it represents, can be interpreted by applying the transform to a unit sphere. The volume of the resulting ellipsoid corresponds to the overall scaling of the developing structure. If the ellipsoid is not spherical, its principal axes indicate the directions of maximum/minimum dilation (in the metric-space sense of the word, not to be confused with the homonymous concept in mathematical morphology) [3, 8].

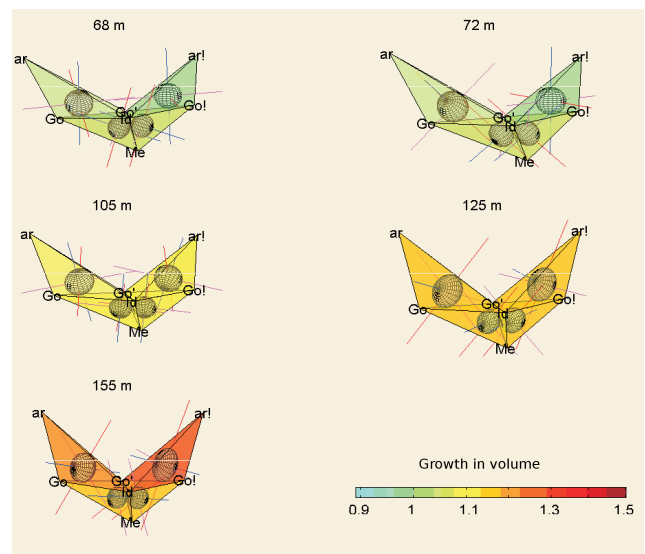


Fig. 6. Local anisotropic growth estimated in regions of a mandible at five different ages of the patient (68 to 155 months); represented as deformation ellipsoids

The deformation tensor is a measure of 3D growth and can be used both as a means of monitoring change and of predicting future development (in a limited time frame and under smoothness assumptions, such as that the development is steady and not disrupted by an operation).

The formalism of the deformation tensor has so far only been used to describe bone growth [1, 8], but it is also readily applicable to the layers of soft tissue comprising the face.

3.3. The bone → skin and other soft tissues aspect. Determining the appearance of the face for a given shape of the underlying bone structure is a problem known in archaeology and forensic science, where faces of deceased persons are reconstructed from their skulls. A common technique used in those research areas is to attach *dowels* (short pegs or pins) to various points on the surface of the skull. The length of each dowel corresponds to the estimated total thickness of the missing soft tissues (muscle, fat, and skin) at the given point. The skull is then covered with clay or similar material, formed to this thickness. This technique ensures that the overall shape of the reconstructed face is compatible with the proportions of the skull, however, the detailed features are left to the artist's (or technician's) imagination.

We have emulated this technique by digital means, applying virtual dowels to a 3D mesh representing the shape of the skull of a living person will have after some intended treatment. Our situation [9, 10] differed from that in archaeology or forensics in that we had a richer set of data:

- Given: Current shape of skull: S1 (from a CT scan) and of the face: F1 (optical scanning).
- Given: Future shape of skull: S2 (predicted from intended treatment).
- Unknown: Future shape of face: F2.

The following notation illustrates the task, with the quotation mark representing the unknown value:

T1: S1 F1

T2: S2 ?

As F1 is known, we do not need to resort to artistic visions to recreate F2. Instead, selected points of F2 are determined by the dowel technique, and the complete surface of the face is obtained by morphing F1 to match those points.

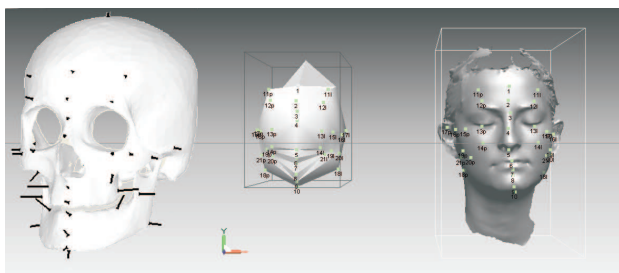


Fig. 7. Stages of face reconstruction using virtual dowels

3.4. The skin and other soft tissues → bone aspect. This processing route is intended to reduce X-ray exposure especially in young patients. As CT is an invasive technique, we try to limit its use. We believe that, after an initial CT scan is made at some point in time T1, some information about the present (T2) shape of the bone structure can be deduced from the current external shape of the face (F2) as scanned with visible light. The task is represented by the following diagram:

T1: S1 F1

T2: ? F2

3.5. Verification. Some patients will be given another CT scan for medical reasons, regardless of our efforts to determine their skull shape from facial scans alone. In such cases our results can be directly verified by comparing them to the CT image at time T2.

In other cases ordinary 2D X-ray images can be used, which also involves some radiation exposure. We have implemented a virtual X-ray machine which optimizes its projection parameters so as to match the real X-ray image.

3.6. The longitudinal reference study. To develop our model, we need data about the normal development of the shape of a child's face over time. Such knowledge should be incorporated into the model so as to better predict the complex interaction between natural growth, pathological changes and medical intervention. For example, when planning an operation on a young patient, it is necessary not only to plan the shape and position of bones after the procedure, but also to consider how much growth and in what directions (bone growth being anisotropic) can be expected in each part at various stages of life. While we do have an extensive database of visible-light scans and CT images of orthodontic patients, few of them have been with the project long enough to provide any meaningful longitudinal information, and obviously none of them exhibited normal development of the facial structures. Therefore, eight healthy children from our own families have been asked to regularly pose for face scans at six-months intervals. At the moment of writing this paper, we have scans from four such time instants, and we plan to continue gathering them as long as possible, hopefully through the children's adolescence.



Fig. 8. Nephew of one of the authors being scanned

4. Unsolved problems and further challenges

We are looking for partners to create an interdisciplinary team, to continue working on modeling the full developmental mechanics of the human head. The following particular issues seem the most urgent at the moment (others will certainly come into sight as the work progresses):

- modeling the shape of the muscles, and their interaction with the changing bone structure;
- parametrizing shape and change in a way that will allow meaningful statistical analysis;

- defining reference coordinate systems for various diagnostic and treatment procedures;
- further developing algorithms for the detection of landmarks in 2D and 3D images;
- facilitating virtual operations to test intended surgical procedures before applying them to the patient.

5. Our equipment

Our laboratory has a rich array of 3D image acquisition and presentation devices:

Scanners:

The MINOLTA VI-9i : a short-range general-purpose 3D laser scanner.

The 3DMD specialized structured-light face scanner.

The Faro Platinum Arm with a laser scanner attached, for objects with complicated shapes and difficult access.

The FARO LS880 HE40 long-range scanner for large objects. 70 m range, 3 mm/10 m precision.

3D output devices:

3D printer: Dimension Elite, producing solid models up to $200 \times 200 \times 250$ mm, layer thickness 0,178mm

3D projector: 3D Barco Galaxy 7 (1400×1050), active 3D goggles (LCD shutter glasses) and large cylindrical screen.

Human motion interface devices:

Body suit: ShapeWrap III, following the wearer's position and movements, wireless connection.

Glove: Shape HandPlus

Tactile-feedback glove: Immersion CyberForce

Robot:

A Pioneer P3 AT robot with a PTZ camera, a stereo pair of cameras, sonars, laser distance finder and a gripping arm.

Acknowledgments.

This work was partly supported by the Polish Ministry of Science and Higher Education.

REFERENCES

- [1] A. Tomaka and K. Skabek "Automatic registration and merging of range images of human head", *Proc. XI Int. Conf. Medical Informatics and Technology* 1, 75–81 (2006).
- [2] K. Skabek and A. Tomaka, "Automatic merging of 3D attribute meshes", *Computer Recognition Systems: Computer Recognition Systems 2, Advances in Soft Computing* 45, 196–202 (2007).
- [3] A. Tomaka, "Digital image sequence-based, deformation detection and description", *Ph.D. Thesis*, Silesian University of Technology, Gliwice, 2001, (in Polish).
- [4] B. Grayson, C.B. Cutting, F.L. Bookstein, H. Kim, and J.G. McCarthy, "The three-dimensional cephalogram: theory, technique, and clinical application", *AJODO American J. Orthodontics and Dentofacial Orthopedics* 94, 327–337 (1988).
- [5] A. Tomaka and L. Luchowski, "Stereovision techniques for the three-dimensional cephalogram", *E-he@lth in Common Europe* 1, CD ROM (2003).
- [6] A. Tomaka, M. Tarnawski, L. Luchowski, and B. Liśniewska-Machorowska, "Digital dental models and 3D patient photographs registration for orthodontic documentation and diagnostic purposes", *Computer Recognition Systems 2, Advances in Soft Computing* 45, 645–652 (2007).
- [7] A. Tomaka, S. Trzeszkowska-Rotkegel, and M. Tarnawski, "Correction of error in 3D reconstruction induced by CT gantry tilt", *J. Medical Informatics & Technologies* 12, 169–175 (2008).
- [8] A. Tomaka and L. Luchowski, "Computer-aided longitudinal description of deformation and its application to craniofacial growth in humans", *Archives of Theoretical and Applied Mechanics* 4, 323–342 (2003), (in Polish).
- [9] K. Więckowska, A. Tomaka, and R. Winiarczyk, "System for facial tissue reconstruction based on dowel method", *Proc. XI International Conf. Medical Informatics and Technology* 1, 383–386 (2006).
- [10] Sz. Kadłubek: "Developing a registration system for multi-modal images", *Master's Dissertatoin*, Silesian Technical University, Gliwice, 2006, (in Polish).