

# Changes in quantitative ultrasound imaging as the predictor of response to neoadjuvant chemotherapy in patients with breast cancer

Hanna Piotrkowska-  
Wróblewska  
Department of Ultrasound  
Institute of Fundamental  
Technological Research PAS  
Warsaw, Poland  
h Piotrkowska@ippt.pan.pl

Katarzyna Dobruch-Sobczak  
Department of Radiology  
Maria Skłodowska-Curie  
National Research Institute of  
Oncology  
Warsaw, Poland  
kdsobczak@gmail.com

Magdalena Gumowska  
Department of Radiology  
Maria Skłodowska-Curie  
National Research Institute of  
Oncology  
Warsaw, Poland  
kdsobczak@gmail.com

Jerzy Litniewski  
Department of Ultrasound  
Institute of Fundamental  
Technological Research PAS  
Warsaw, Poland  
jlitn@ippt.pan.pl

**Abstract**— The presented study demonstrates the effectiveness of quantitative ultrasound imaging (H-scan ultrasound) in monitoring the breast cancer response to neoadjuvant chemotherapy and predicting pathological response. A group of 40 patients (51 breast tumors) participated in the study. The results showed that QUS imaging was able to distinguish between breast cancer patients responding and not responding to chemotherapy early in the course of treatment. Analysis of the percentage changes in red in the parametric images showed that this parameter can predict the response to treatment of patients with the area under the receiver operational characteristics (ROC) curve of 0.61, 0.70, 0.83, and 0.86, respectively, one week after 1<sup>st</sup>, 2<sup>nd</sup>, 3<sup>rd</sup> and 4<sup>th</sup> dose of treatment.

**Keywords**—breast cancer, neoadjuvant chemotherapy, ultrasound, H-scan ultrasounds

## I. INTRODUCTION

World statistics show that each year the number of newly diagnosed breast cancer cases exceeds 500,000. These results show that breast cancer accounts for 25.1% of all cancer cases [1]. They rank breast cancer in the first place among other oncological diseases in terms of its incidence in women.

In the case of breast cancer, one of the most frequently used therapies is neoadjuvant chemotherapy (NAC), which is part of the comprehensive treatment of breast cancer. The available results of many clinical trials have shown that neoadjuvant chemotherapy is a very effective method of treatment. In many cases, a complete pathological response is achieved, which translates into the breast conserving treatment and long-term survival of patients. However, some studies have also shown that 10–

35% of patients do not respond to chemotherapy [2]. In these patients, the use of ineffective long-term treatment reduces the chances of recovery and survival. Therefore, monitoring, assessment and prediction of the pathological tumor response to NAC should be precisely performed at each stage of therapy.

The aim of the study was to assess the breast tumor response to neoadjuvant chemotherapy after each chemotherapy cycle using a new ultrasound technique that is able to visualize the relative size of acoustic scatterers - H-scan ultrasound imaging.

Based on the knowledge about the remodeling of the tumor microstructure during chemotherapy, it can be assumed that these changes will also result in visible changes in the ultrasound images.

Tissue remodeling is a multi-step process involving changes in the neoplastic cells (cellular organization, cell modeling and cell death) and changes in the stroma (fibrosis, elastosis, collagenization, microcalcification and neovascularization), with the consequence that these various structures are the main source of scattering of ultrasound in particular phases of treatment.

## II. MATERIALS AND METHODS

### A. Ultrasonic Data Acquisition

The acquisition of ultrasonic RF signals was performed before the start of treatment and one week after each of four courses of chemotherapy. During each examination, data from four cross-sections of neoplastic lesions (radial, radial + 45°, anti-radiative and anti-

radiative + 45°) were recorded. The area of interest was always indicated by the radiologist.

The ultrasound echoes from patients were collected using Ultrasonix SonixTOUCH ultrasound scanner (Ultrasonix Medical Corporation, Richmond, BC, Canada) and a linear probe (L14-5/38) at a center frequency of 10 MHz. The scanner was equipped with an ultrasound research interface enabling the recording of raw post- beamformed RF data.

### B. Patients

40 patients participated in this single center study. Due to the fact that seven women were diagnosed with bifocal lesions and two trifocal lesions in total, 51 lesions were examined and analyzed. The maximum and minimum diameter of the tumors were 40 mm and 5 mm, respectively.

All patients participating in this research agreed to be included in the study, and the study was conducted in accordance with the Declaration of Helsinki. The protocol was approved by the Ethics Committee of Poland (project identification code 49/2018).

### C. Histopathology

Prior to qualification for neoadjuvant chemotherapy, all patients were subjected to core-needle biopsy. On the basis of the obtained tissue material, the pathologist indicated the subtypes of cancer (molecular subtypes and the degree of malignancy). Additionally, after the end of chemotherapy and after surgery, the removed tumors or residual, target intra-mammary lesions were assessed in order to determine the number of residual malignant cells (RMC).

RMC is a parameter that allows you to evaluate the response to NAC. The RMC percentage ranges from 0% to 100%. In the case of complete pathological response, it is 0%, and in the case of complete non-response, it is 100%. In the presented studies, the RMC cut-off was assumed to be  $\leq 30\%$  for responding tumors.

### D. Quantitative Analysis of Ultrasound Data

Two parallel convolution filters were used to the RF data signals in a goal of measure the relative strength of the received time-domain signals against a pair of Gauss-weighted polynomial functions GH2 (t) and GH8 (t) [3]. Using the Hilbert transform, in the next step, the envelope of signal (for each of these filtered and composite data sequences) was then determined. The relative strength of these filter outputs was color coded with lower frequency backscatter signals assigned to channel R (red) and higher frequency components to channel B (blue). In order to quantify the images after each chemotherapy course, the percentage of red in the images was analyzed. Data from four tumor cross section were analyzed as a single set.

This approach allowed for a more detailed analysis of changes in the tumor microstructure than was possible with only one cross-section.

## III. RESULTS

Table I presents the clinical characteristics of group of patients which participated in research. The group consisted of women with an average age of 47 years (range: 32–83).

Histopathological verification before treatment revealed that the tumors comprised invasive carcinoma NST G2 (23 tumors), G3 (9 tumors), and G1 (11 tumors). Moreover, there were 9 luminal A cancers, 25 luminal B, 9 TNBC and 8 HER2+ tumors.

Histopathological examination after final NAC and surgery revealed 29 tumors with 0–30% RMC, 22 tumors with RMC  $\geq 70\%$ .

Figure 1 shows representative H-scan images obtained from a responding patient before and one week after the 1<sup>st</sup>, 2<sup>nd</sup>, 3<sup>rd</sup> and 4<sup>th</sup> cycle of chemotherapy. An overall increase in the percentage of red in the tumor images was detected in responders. Such an increase was not seen in non-responders.

TABLE I. CHARACTERISTICS OF THE PATIENTS' GROUP, INCLUDING HISTOLOGICAL FINDINGS

Category	Characteristics	Count/Value
Patients	Number of patients	40
	Mean age (years)	47
	Age range (years)	32-83
Tumor histology	Invasive ductal carcinoma (IDC)	51
	IDC with ductal carcinoma in situ	20
Receptor status	Luminal A	9
	Luminal B	25
	TNBC	9
	Her2+	8
Pathological response (RMC %)	0-30	29
	31-100	22

Fig. 1 The H-scan ultrasound images obtained for responding patient before and during NAC treatment

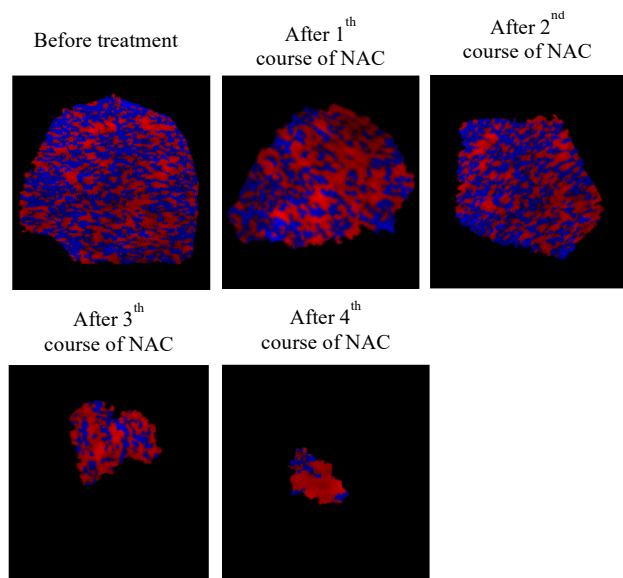


TABLE II. MEAN VALUES OF THE PERCENTAGE OF COLOR RED IN H-SCAN IMAGES BEFORE AND ONE WEEK AFTER THE 1<sup>ST</sup>, 2<sup>ND</sup>, 3<sup>RD</sup> AND 4<sup>TH</sup> CYCLE OF CHEMOTHERAPY FOR RESPONDERS ( $RMC \leq 30\%$ )

Before treatment	After 1 <sup>th</sup> course of NAC	After 2 <sup>nd</sup> course of NAC	After 3 <sup>rd</sup> course of NAC	After 4 <sup>th</sup> course of NAC
38,4 % ( $\pm 7,2$ )	42,6% ( $\pm 8,6$ )	56,7% ( $\pm 11,7$ )	79,1% ( $\pm 9,2$ )	81,6% ( $\pm 14,3$ )

TABLE III. AREA UNDER THE ROC CURVE (AUC) VALUES FOR TREATMENT RESPONSE CLASSIFICATION AT EACH TREATMENT STAGE

After 1 <sup>th</sup> course of NAC	After 2 <sup>nd</sup> course of NAC	After 3 <sup>rd</sup> course of NAC	After 4 <sup>th</sup> course of NAC
0.61	0.70	0.83	0.86

The mean percentages of red in the tumor images obtained in responder patients are shown in Table II.

Statistical analysis was performed to differentiate the group of responders and non-responders based on the quantitative analysis of the H-scan images. The statistical significance of differences between the groups responding to NAC and the groups that did not respond was assessed using the p value. Starting from the second cycle of chemotherapy, statistically significant differences were observed in the values of the analyzed parameter ( $p < 0.05$ ).

Table III presents AUC values for the analyzed parameter as a function of chemotherapy courses. It can be seen that the encouraging effects were obtained after the second treatment dose ( $AUC = 0.7$ ). The best results were obtained after the fourth cycle of chemotherapy, the quantitative parameter predicted response to treatment with an  $AUC \geq 0.86$ .

#### IV. DISCUSSION

The results presented in this study showed the high potential of a biomarker of H-scan images to predict the response of breast cancer patients to chemotherapy immediately after starting treatment. The conducted analysis showed that the responding and non-responding patients showed significantly different trends in changes that were observed in the H-scan images at individual stages of treatment.

The information available in the literature on changes in tumor microstructure as a result of successful treatment seems to be consistent with the observations in this study. Neoplastic tumor remodeling is a multi-stage process that includes changes in neoplastic cells and changes in the stroma. The results of previous in vitro and in vivo studies available in the literature have shown that the processes accompanying cell apoptosis (nuclear condensation and fragmentation) can modify the properties of ultrasonic tissue scattering [4-6]. Especially Banihashmei et al. showed that cell-based scatterers, which change with cell death, can influence ultrasonic backscatter signals at the clinical frequency of ultrasound [7]. These processes are most likely the source of the changes observed in the H-scan images at the beginning of the treatment.

Changes in the stroma: fibrosis, elastosis, collagenization, microcalcification and neovascularization observed in the subsequent treatment phases also change the dominant sources of ultrasound scattering. This was confirmed by the results of the work of Beak [8]. The level of fibrosis has been shown to be strongly correlated with lower frequency scattering and is reflected in the H-scan images.

#### V. CONCLUSION

In sum, this paper presents the effectiveness of the ultrasonic H-scan imaging in predicting results of neoadjuvant chemotherapy in patients with breast cancer early in the course of treatment. The results presented here confirm the suitability of quantitative ultrasonic imaging in monitoring results of treatment. In the near future studies validating these initial, single-center findings are planned.

#### ACKNOWLEDGMENT

This work was supported by National Centre for Research and Development (NCBiR) under the grant agreement LIDER/24/0088/L -11/19/NCBR/2020 and National Science Center of Poland grant 2019/35/B/ST7/03792.

#### REFERENCES

- [1] J. Ferlay, M. Colombet, I. Soerjomataram, T. Dyba, G. Randi, M. Bettio, "Cancer incidence and mortality patterns in Europe: estimates for 40

- countries and 25 major cancers in 2018”, *Eur J Cancer*, vol. 103, pp 356–387, 2018.
- [2] F. Prihantono, “Breast cancer resistance to chemotherapy: When should we suspect it and how can we prevent it?”, *Ann Med Surg (Lond)*, vol. 70, 102793, September 2021.
- [3] K.J. Parker, “Scattering and reflection identification in H-scan images”, *Phys Med Biol* 2, vol. 61, pp.20–28, 2016.
- [4] R.M. Vlad, S. Brand, A. Giles, M. Kolios, G. J. Czarnota, “Quantitative ultrasound characterization of responses to radiotherapy in cancer mouse models”, *Clin. Cancer Res*, vol.15, pp. 2067–2075, 2009.
- [5] A. Sadeghi-Naini et al., “Low-frequency quantitative ultrasound imaging of cell death *in vivo*”, *Med. Phys.*, vol. 40, pp. 82901, 2013.
- [6] G. J. czarnota et al. „Ultrasonic biomicroscopy of viable, dead and apoptotic cells”, *Ultrasound Med. Biol.* vol.23, pp.961-965 23, 1997.
- [7] B. Banihashemi et al., “Ultrasound imaging of apoptosis in tumor response: novel preclinical monitoring of photodynamic therapy effects.” *Cancer Res*, vol.. 68, pp. 8590-8596, 2008.
- [8] J. Baek, “H-scan analysis for differentiation of melanoma metastases and evaluation of treatment response”, AIUM 2022, San Diego.